



Study club surgery

11/11/23

Pat M HH

- ▶ 71 year old man
- ▶ 2 hip replacements
- ▶ High blood pressure

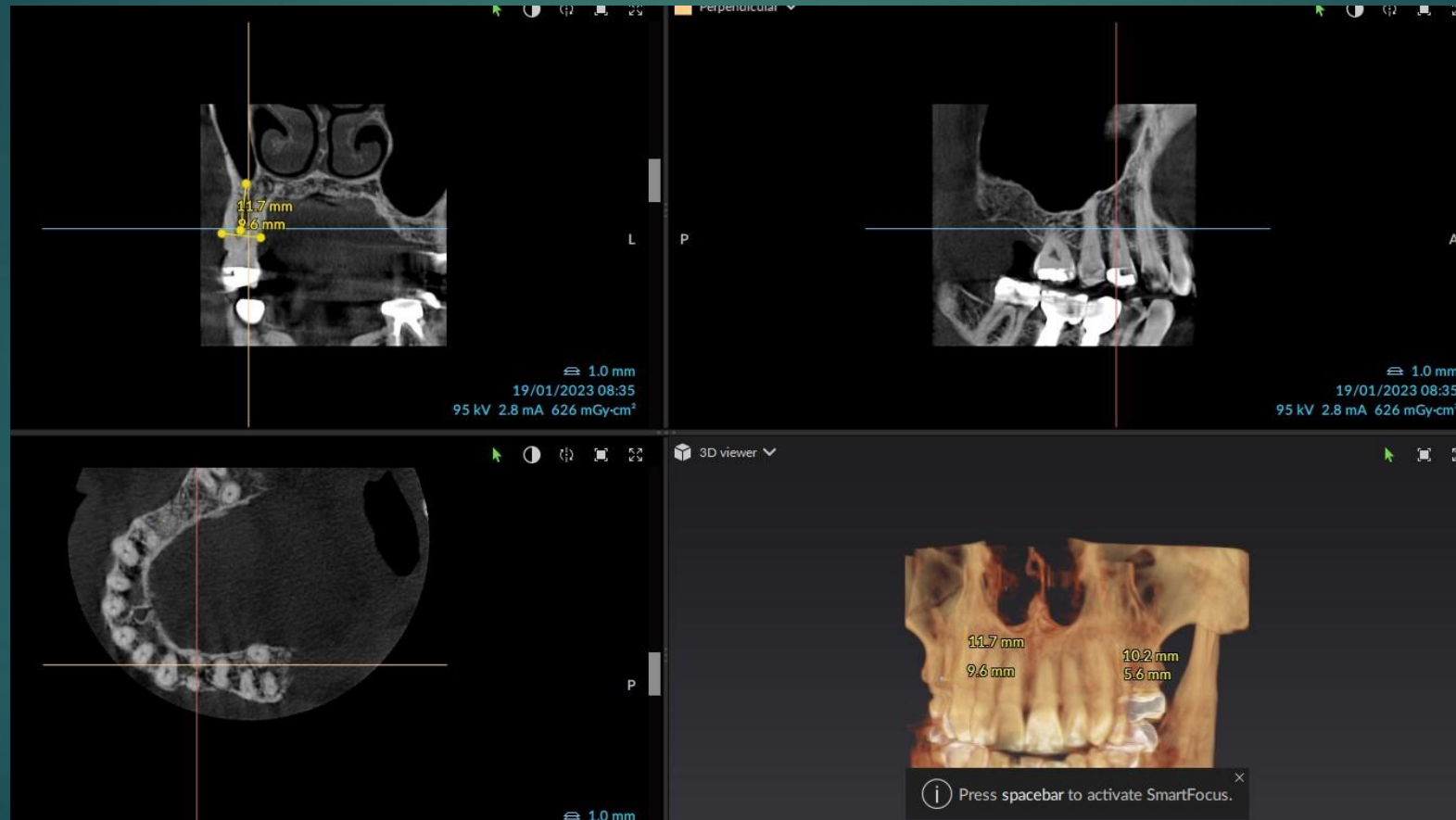
Vertical root fracture #5

Missing tooth #13/14

- ▶ Original plan was lateral wall sinus lift #13/14 and 2 implants.
- ▶ 10/31/23 pain on UR.
- ▶ #5 – 6 mm pocket on M and D, clinical M crack. Pain to bite and percussion. NR to cold and EPT = necrotic with vertical root fracture and symptomatic periodontitis.
- ▶ Due to financial reasons pt opts to change plan.

- ▶ New plan Immediate implant #5
- ▶ Implant #13

CBCT #5 – immediate implant 3.7 x11.5



CBCT #13

Implant 3.7 x 10

