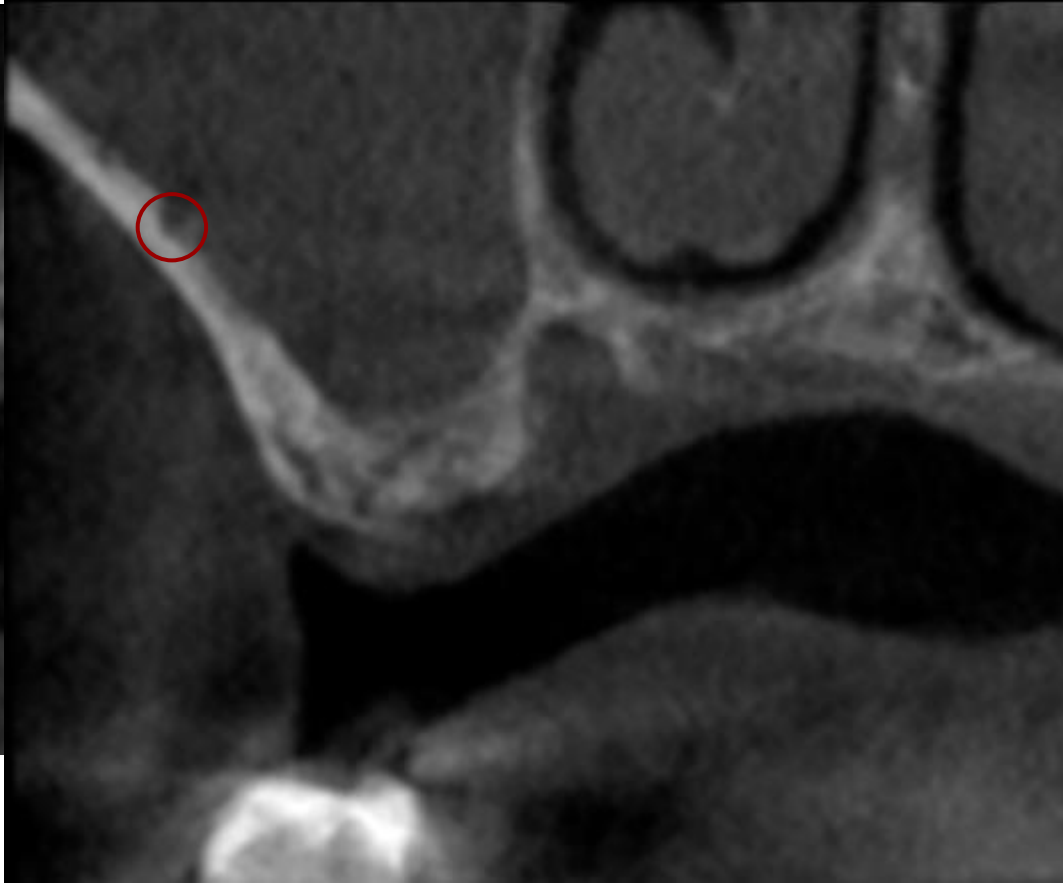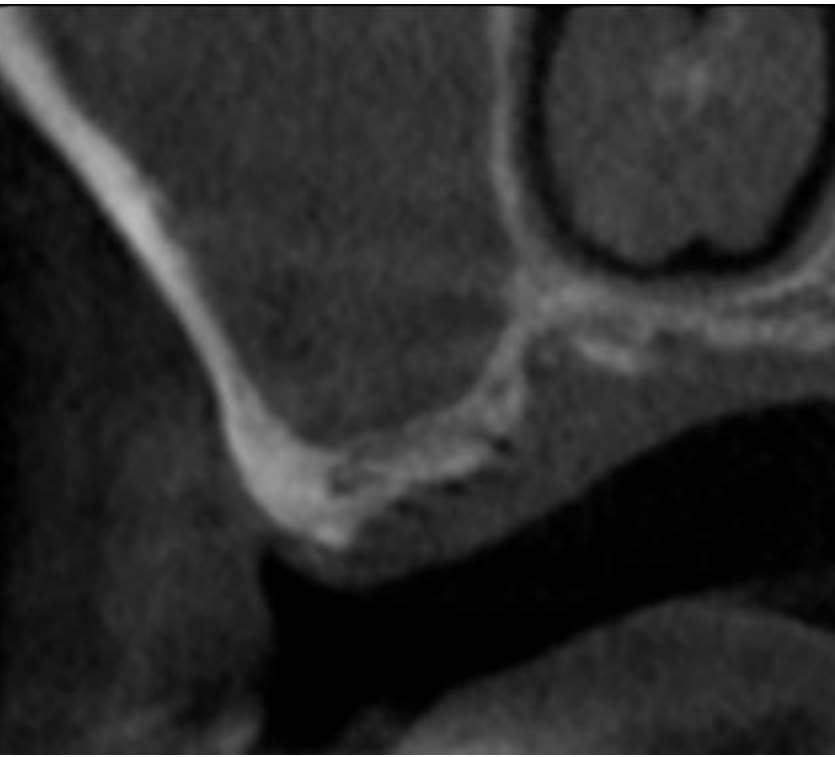


# Jeff P.

- 63YOM
- Being treated for HBP and Hypercholesterolemia with Atorvastatin, Omelsartan, and Lipitor. Had a stent placed in 2005.
- Interested in replacing his back tooth without a removable prosthetic.
- Started pt on Augmentin and Fluticasone nasal steroid. Stated he felt under the weather on day of CBCT. Declined ENT referral stating he felt much better afterwards.



# Clinical Plan

Access and elevate membrane.

Place bone graft.

Primary Closure.

