

Free Gingival Graft with Frenectomy

Gavin McNelis DDS

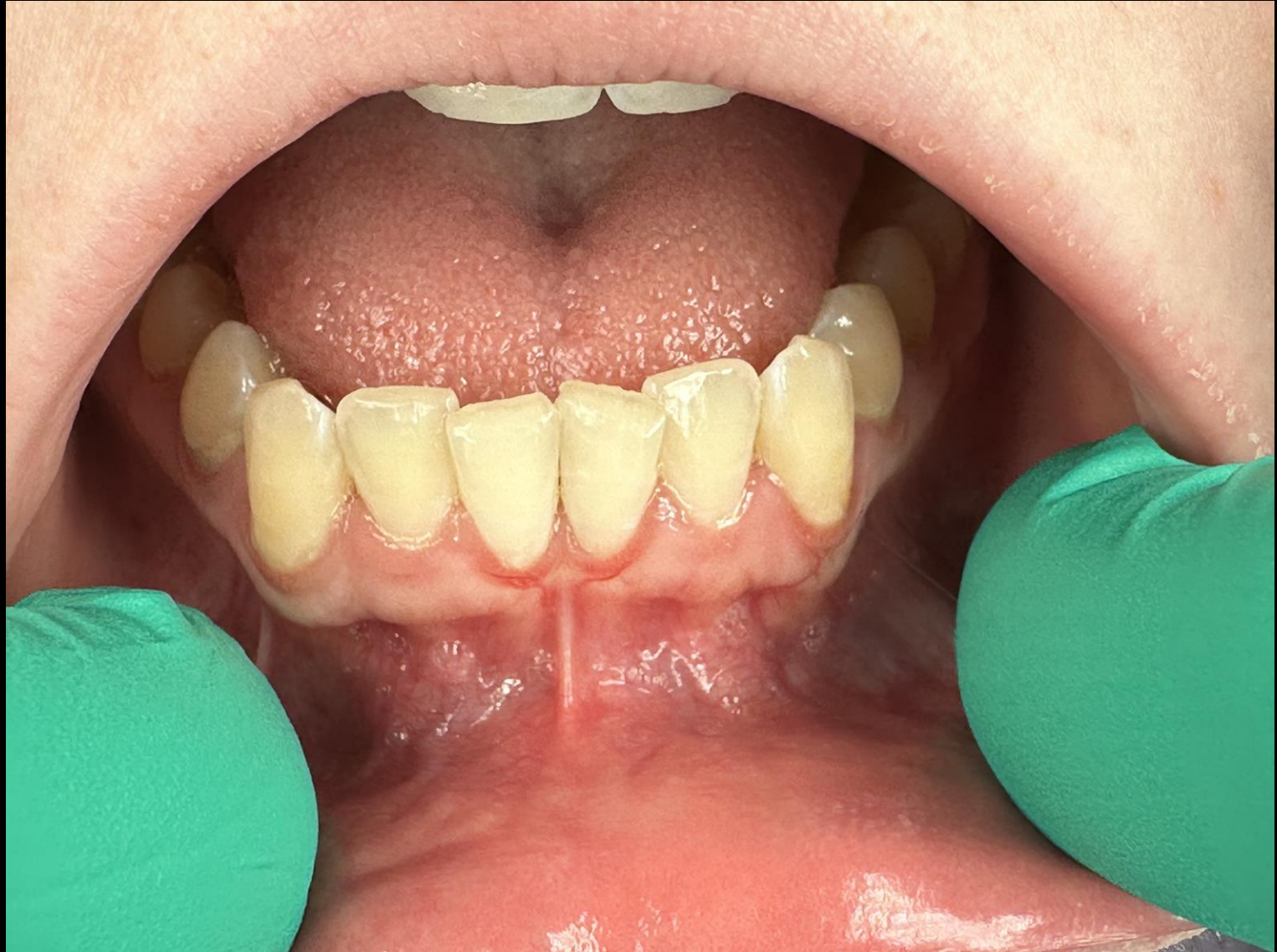IEPSC 03/2023

Patient: Amy

- 25yo Female
- RMH: No significant findings.
- Dental History:
 - History of ortho around age 15
 - Thin KT #24 and #25 with high frenum attachment. Noted since 2016
- Losing parent's insurance end of March

Pre-op

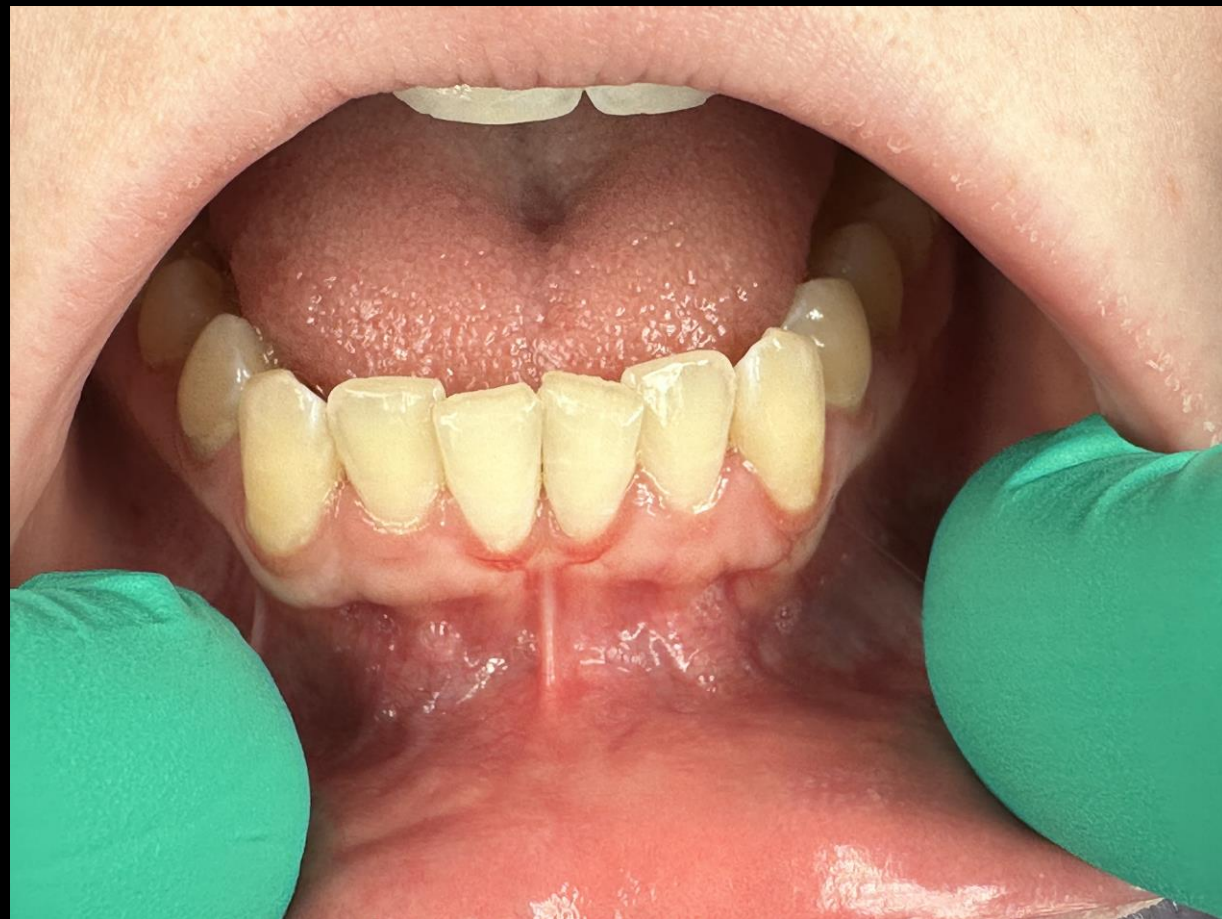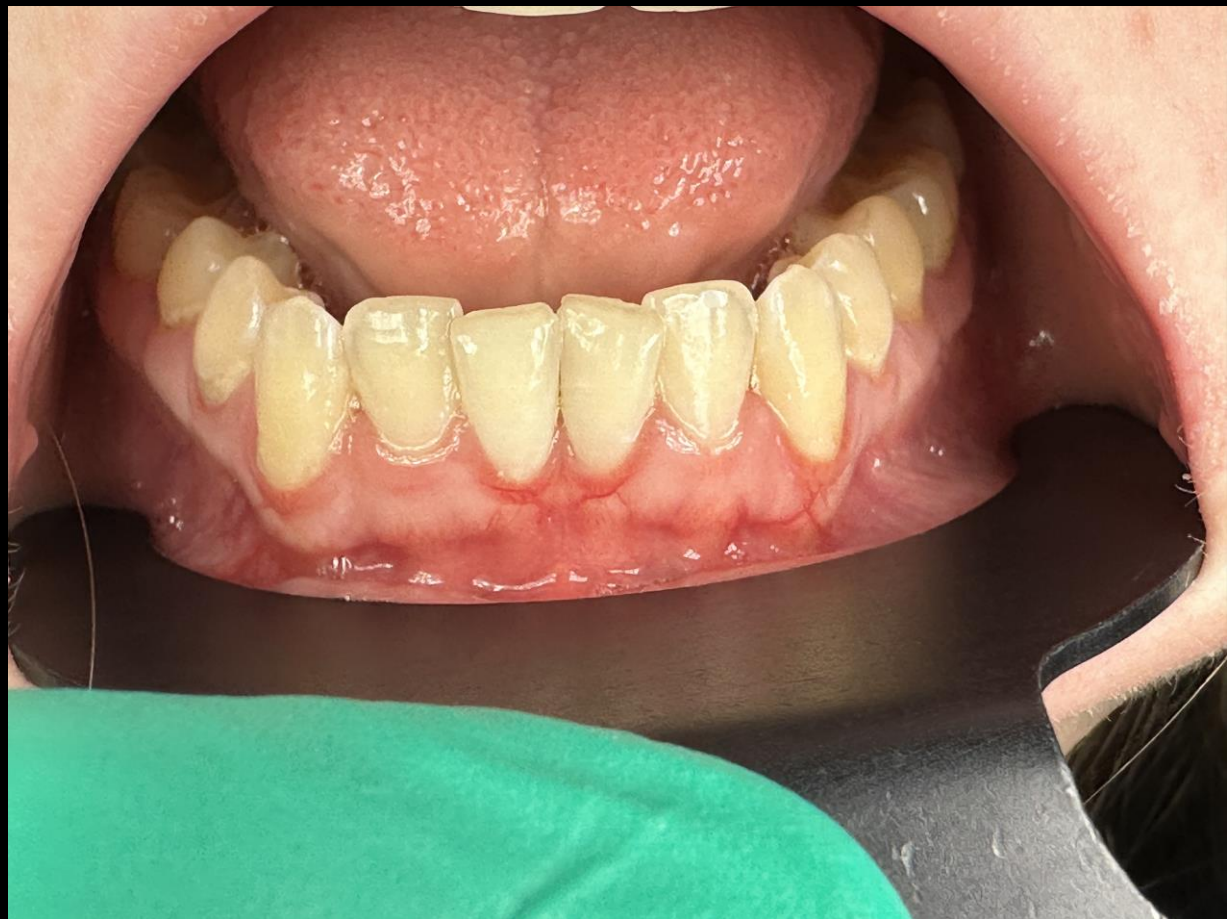- Minimal KT #24/25
- Shallow Vestibule
- High frenum attachment
- PD have been stable, 2-3mm



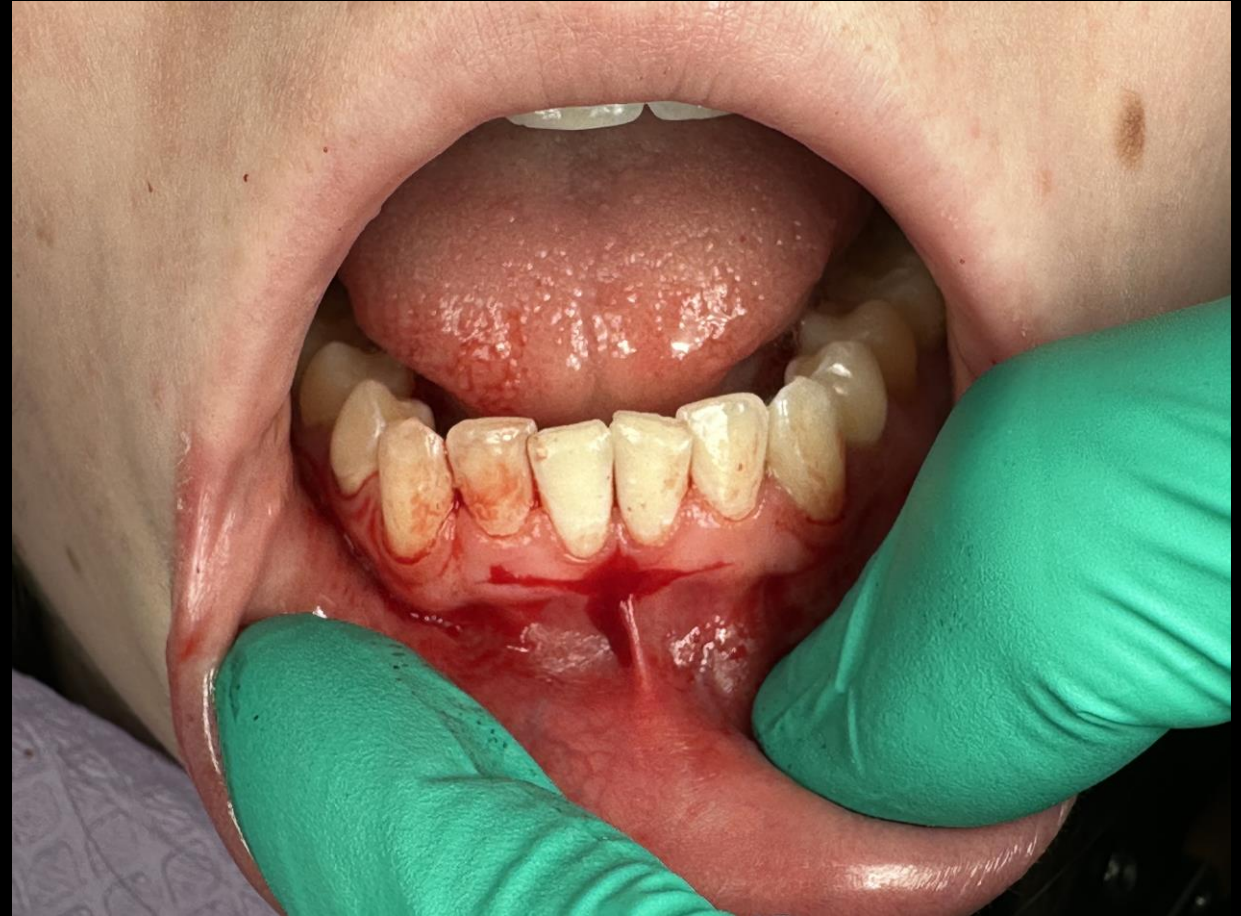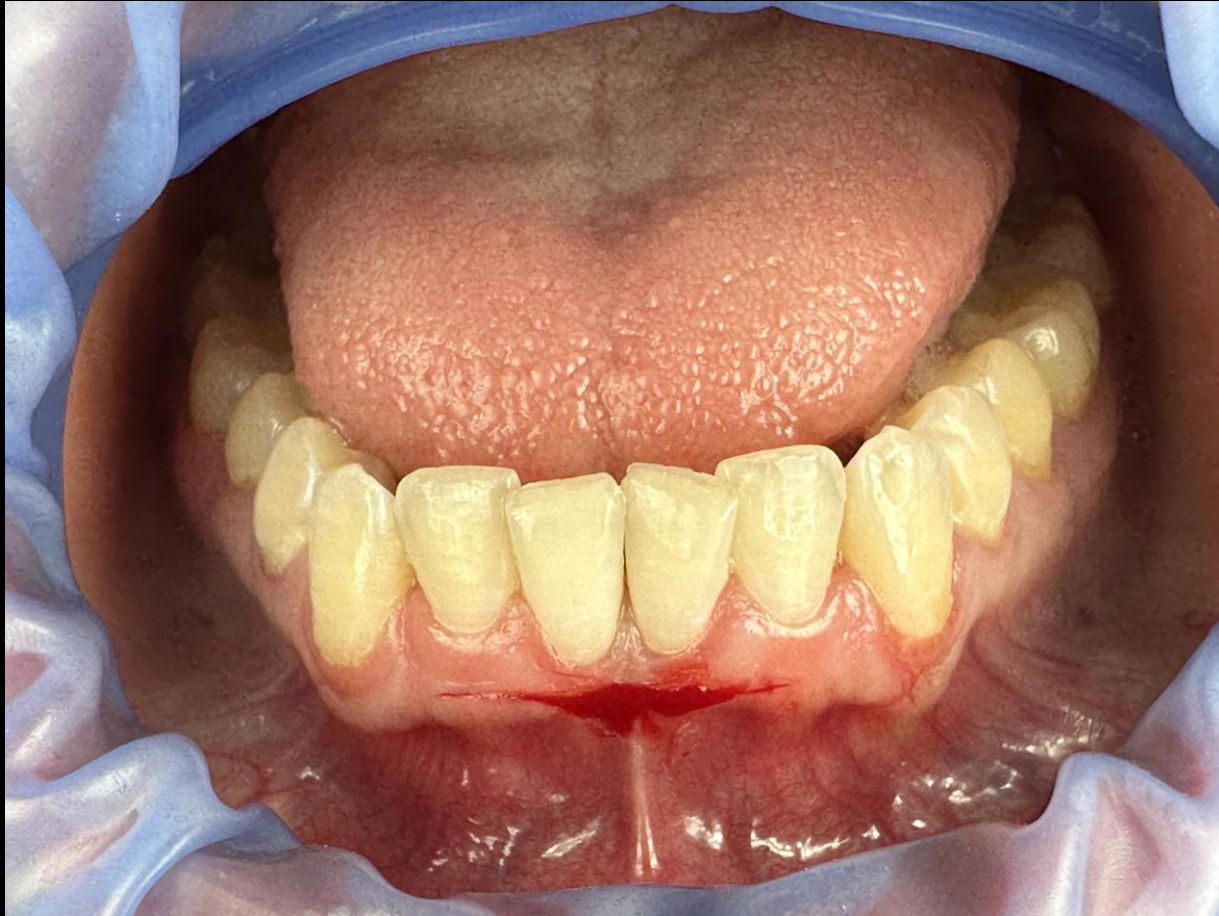Treatment Plan:

- Free Gingival graft with frenectomy.
 - Thicken KT tissue band of #24/25
 - Release frenum
 - Deepen vestibule

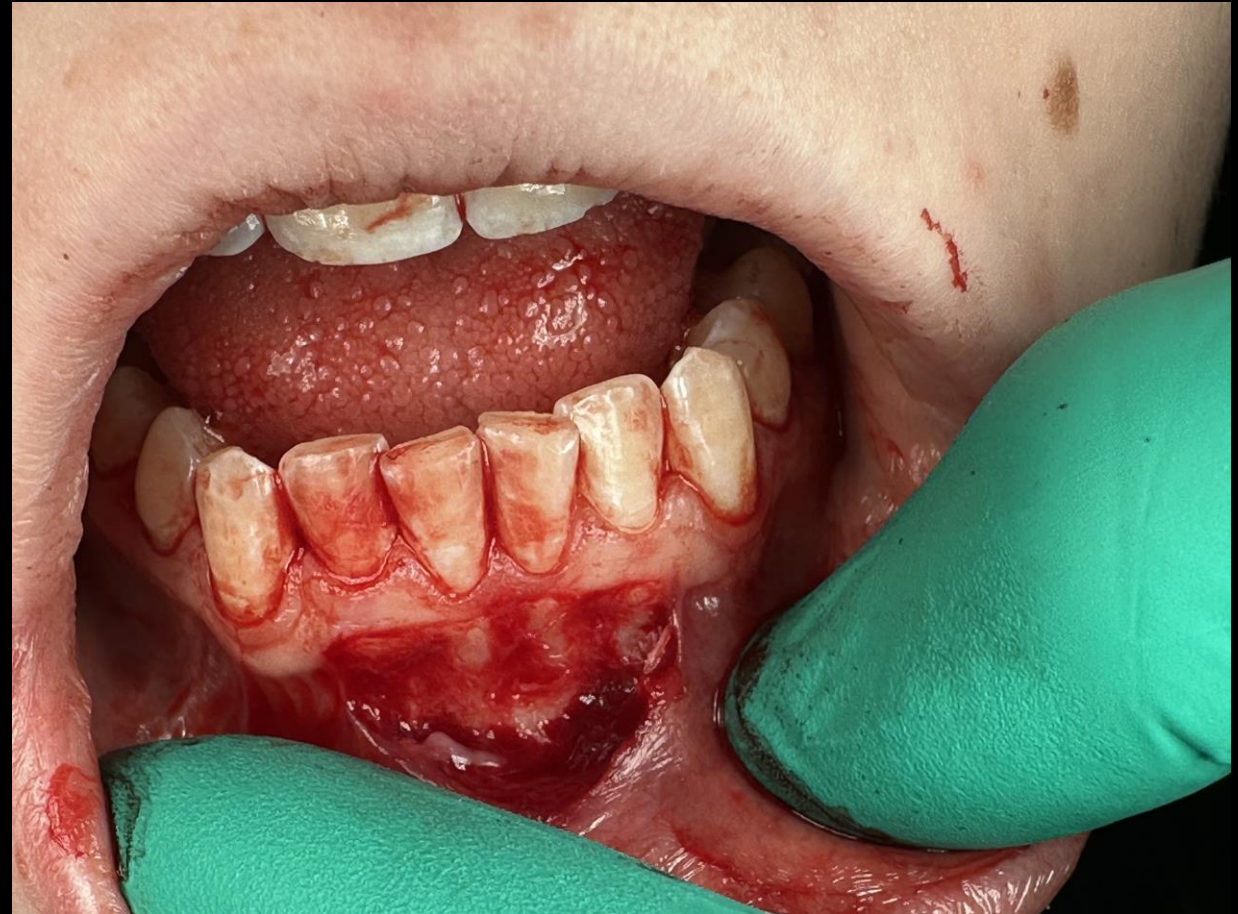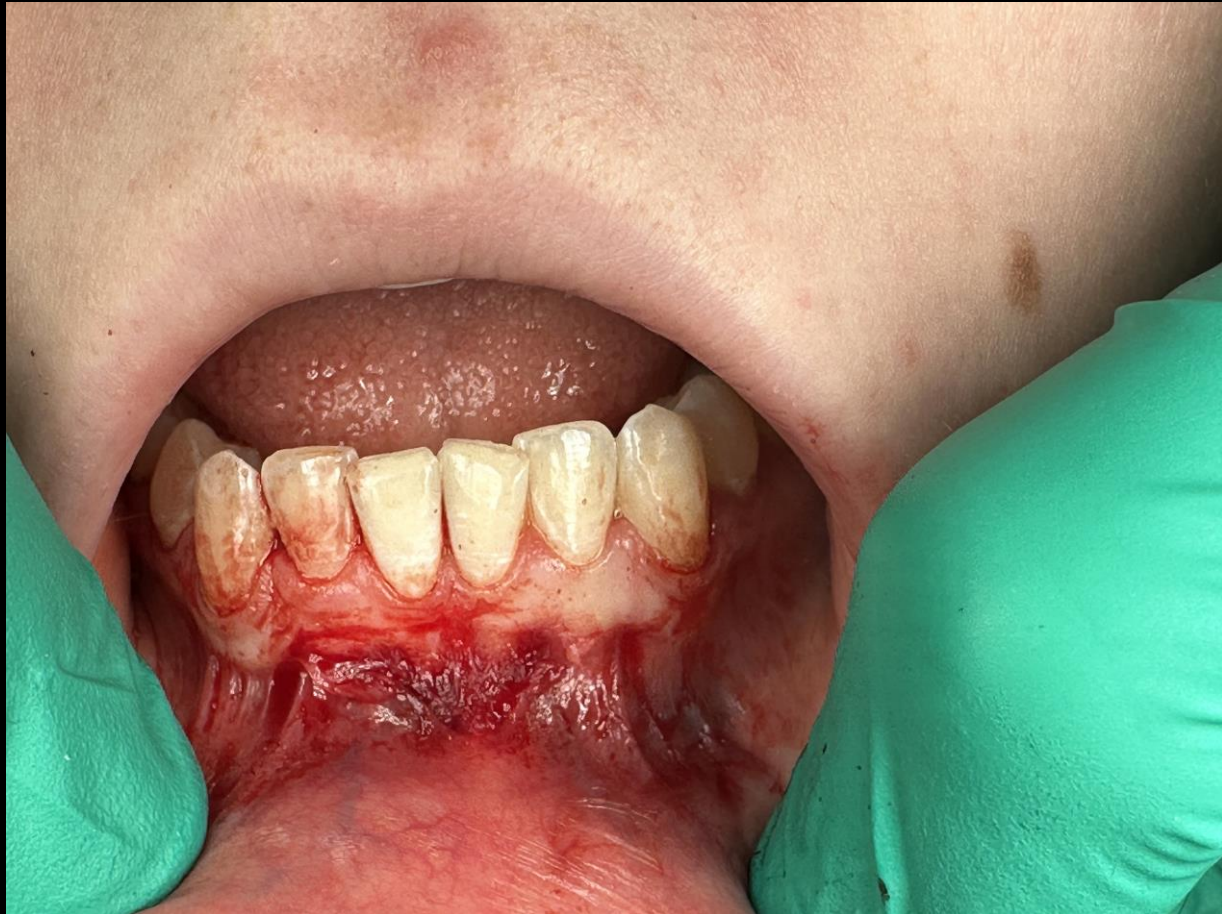Pre-op:



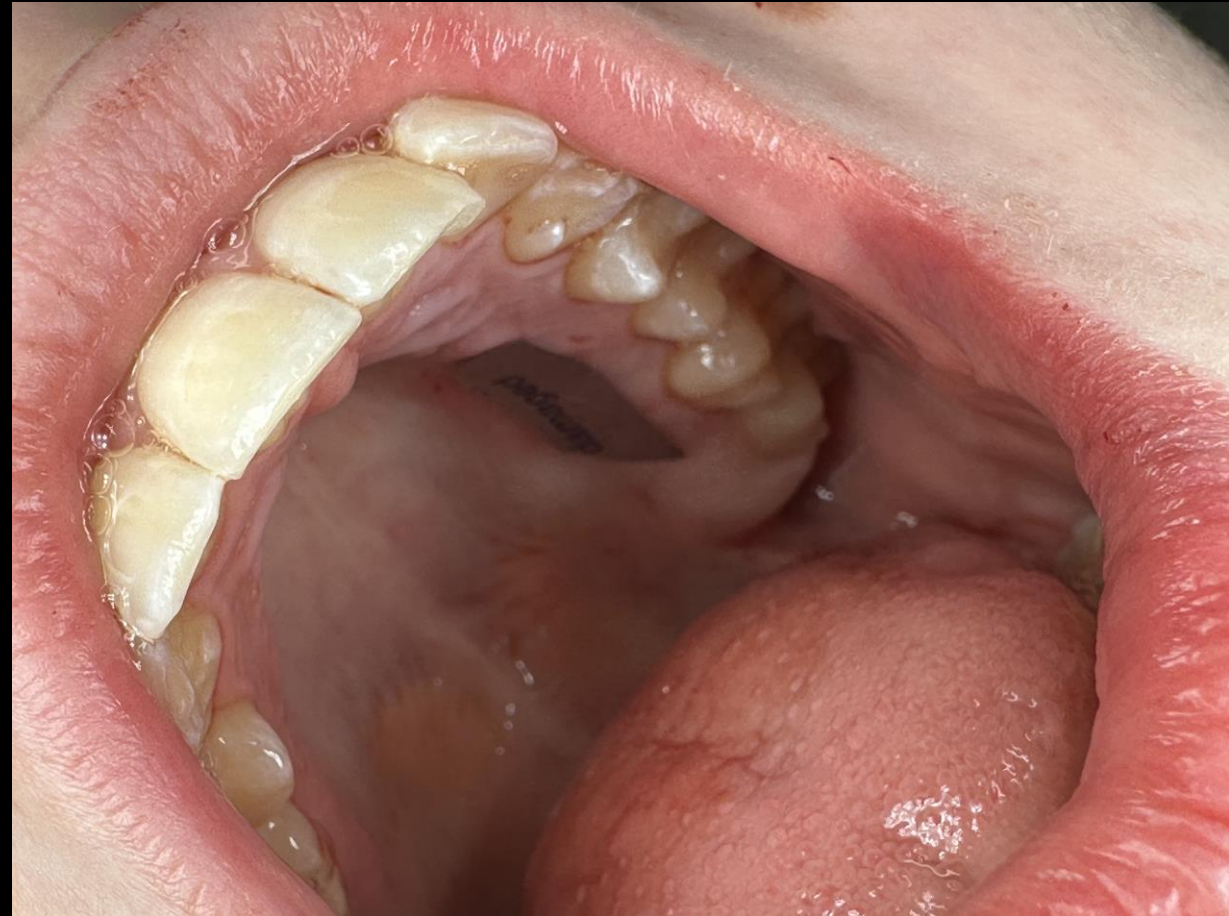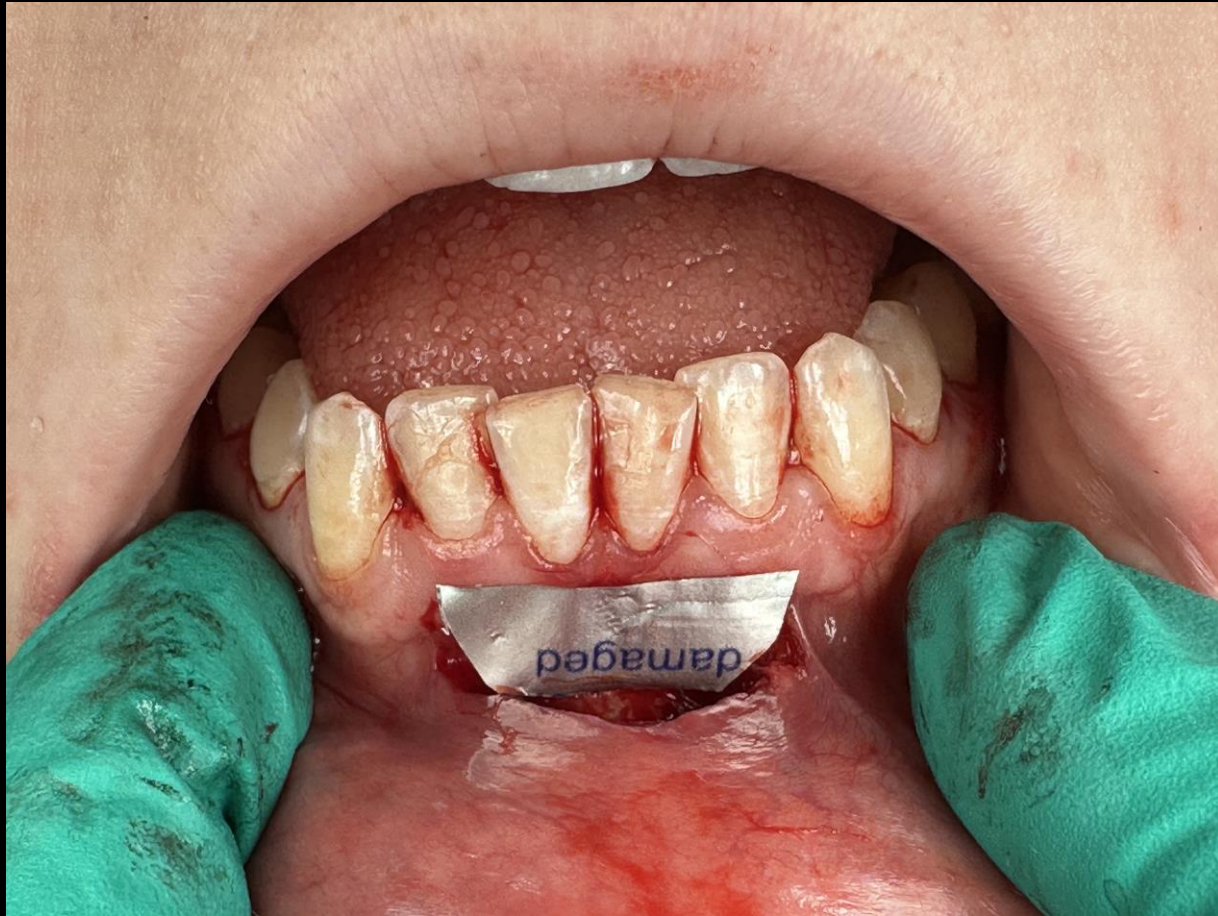Initial beveled incision



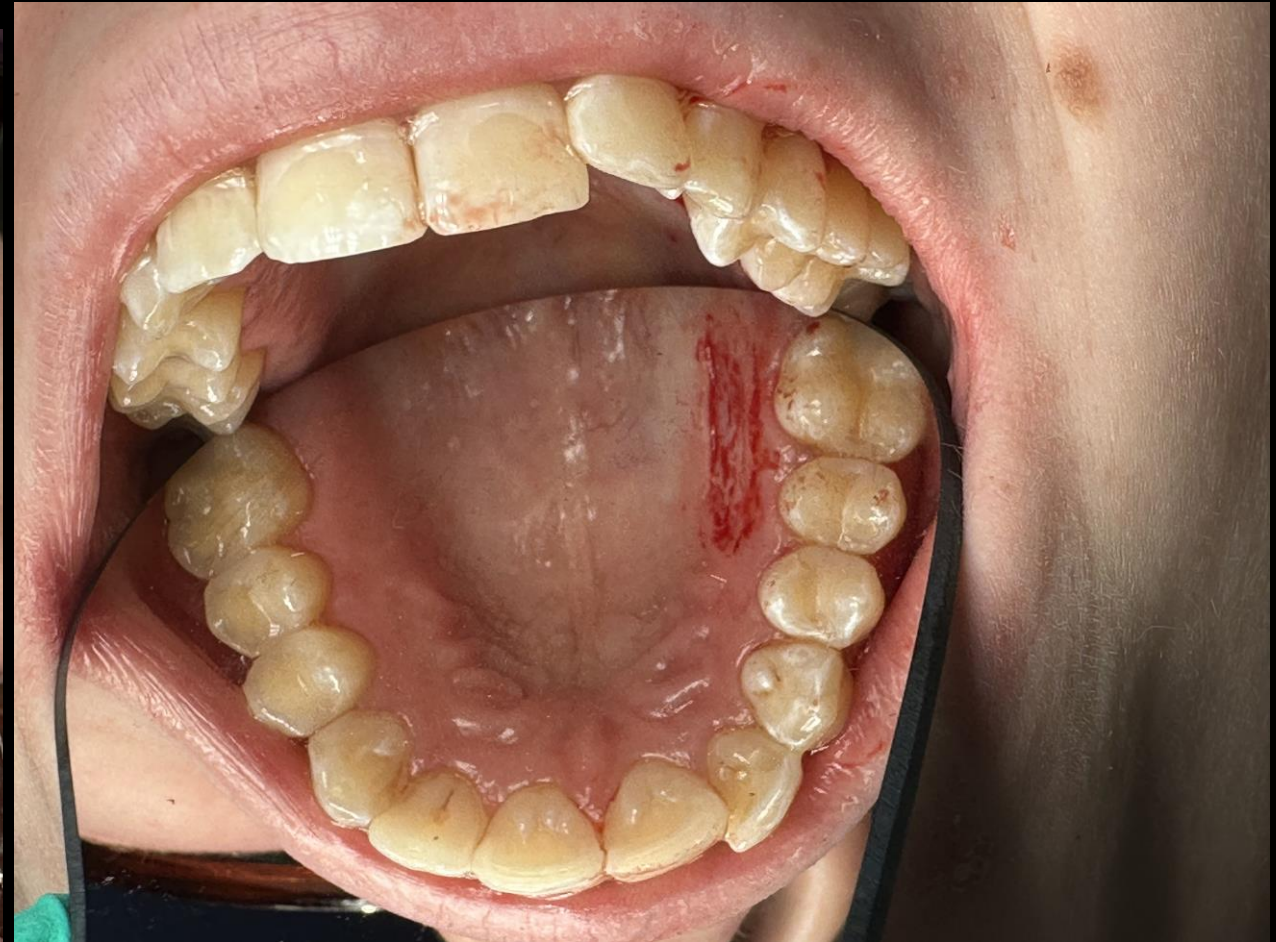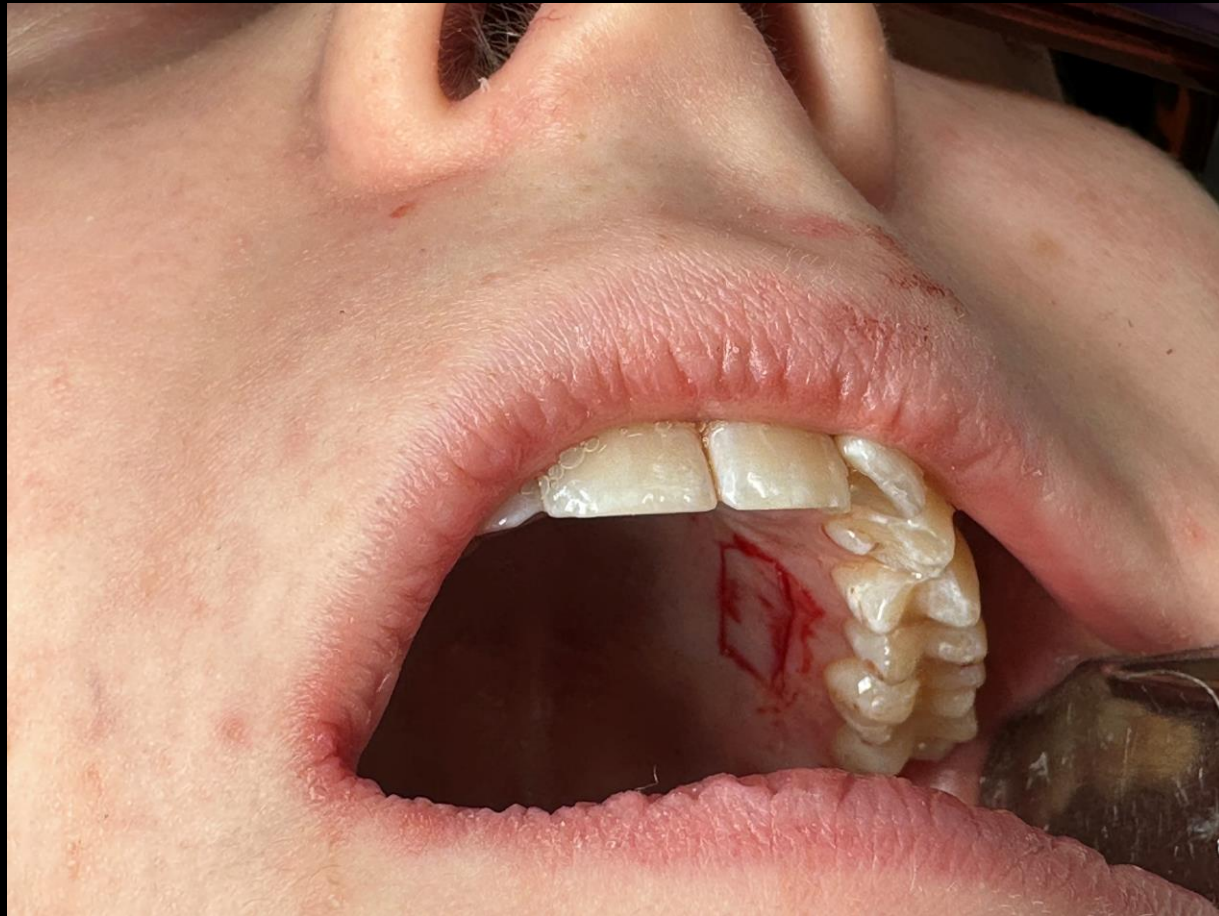Preparation of recipient site



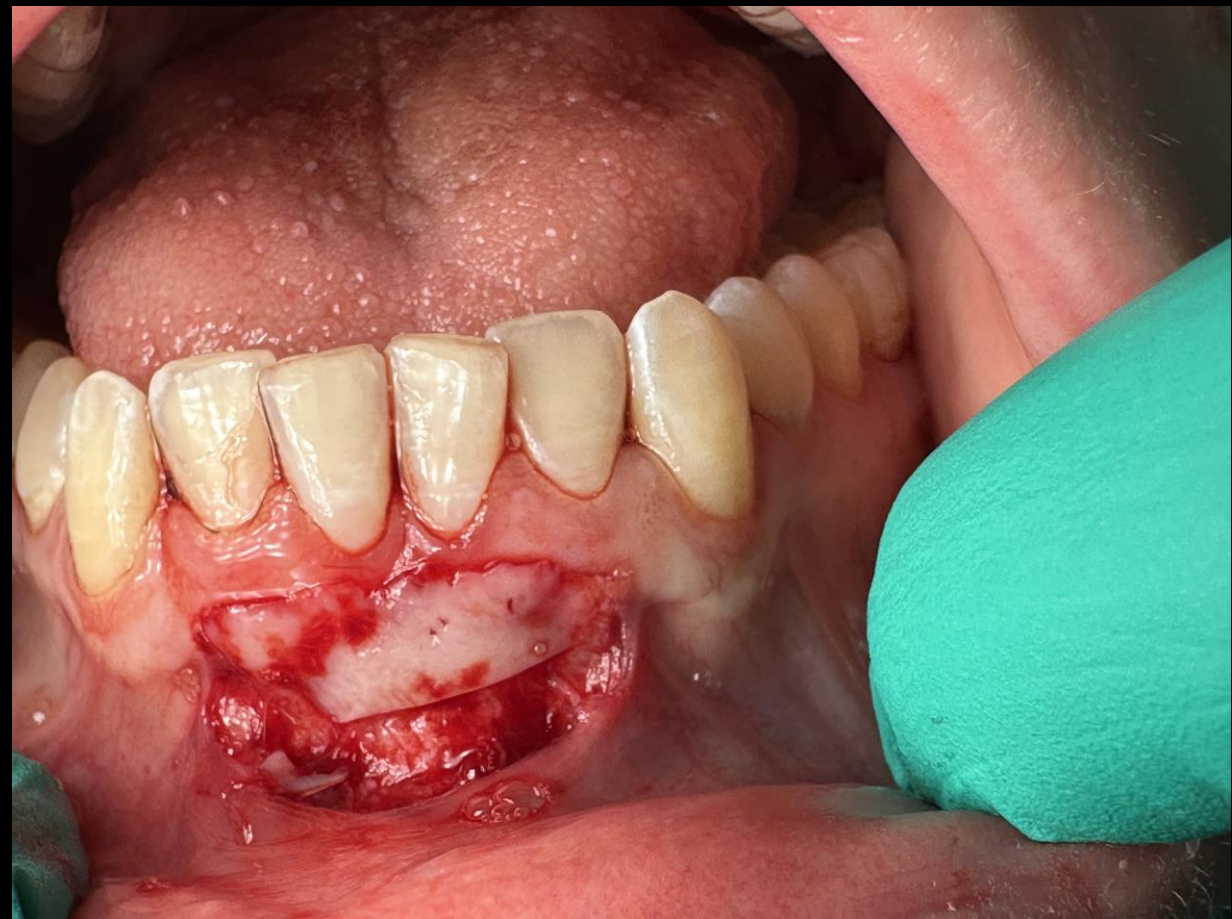
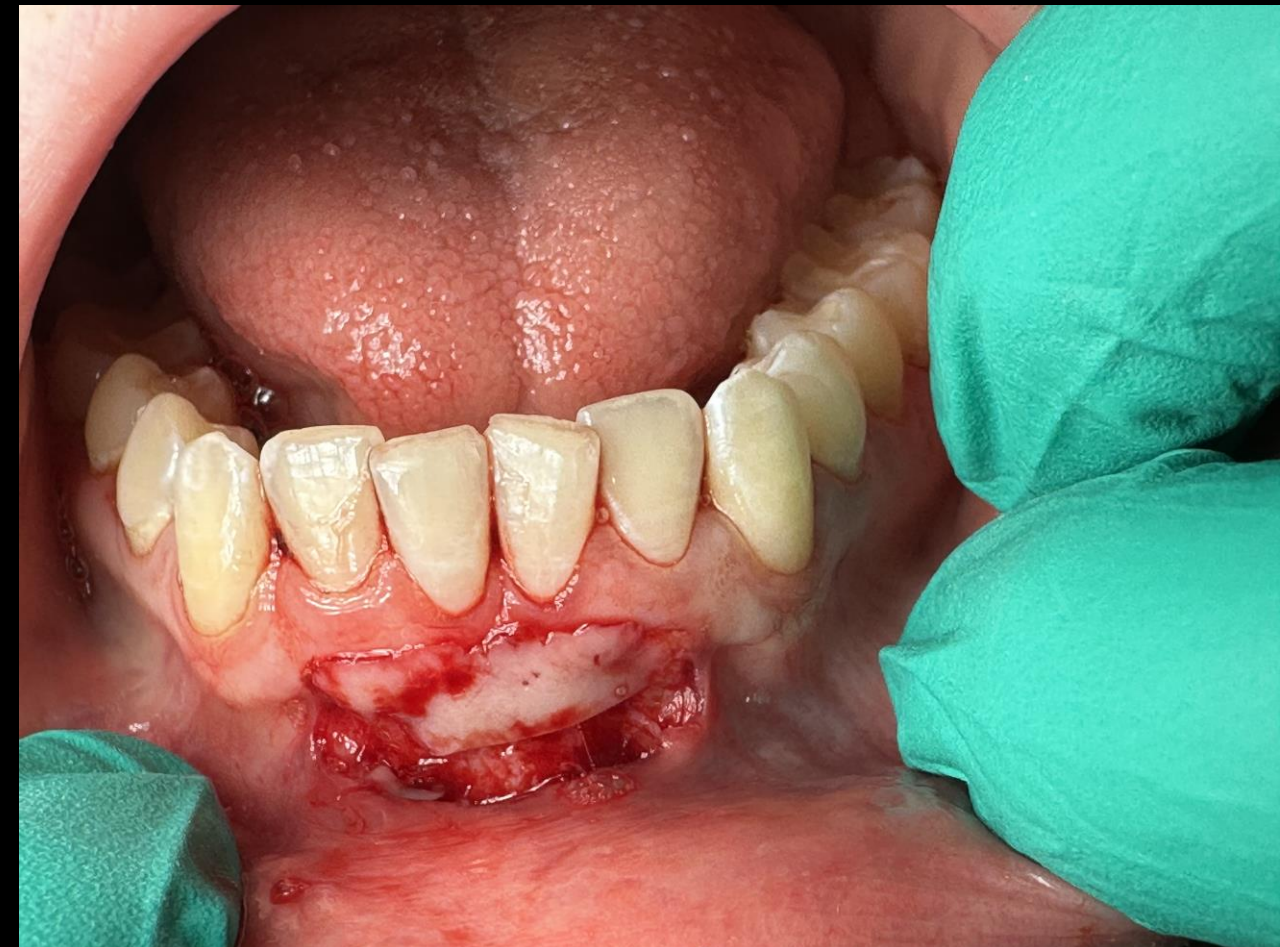Donor site template



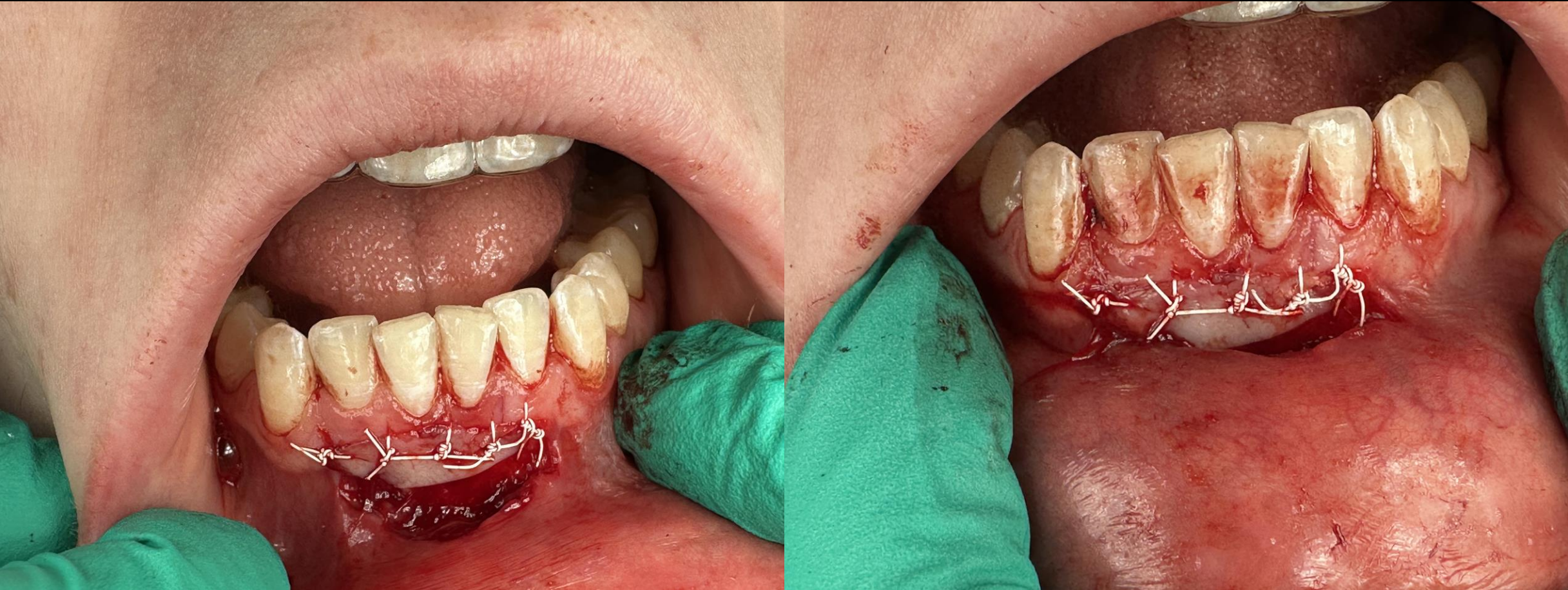Harvest Site



Positioning graft



Suturing graft



Finalize with COE pack + Palatal stent

